

Potential Clinical Applications of Plaque Imaging by CTA: A Survey

Harvey S. Hecht MD, Stephan Achenbach MD, Jagat Narula MD, PhD

The rapid growth of coronary computed tomographic angiography (CTA) has been accompanied by robust prognostic data and the development of guidelines and appropriateness criteria. Clinical applications are based predominantly on stenosis measurements. However, the specific insights offered by plaque analysis have not yet resulted in their incorporation either into formal documents or clinical practice. Nonetheless, since plaque data is available in every CTA, should it be incorporated into clinical care?

We would like to systematically collect information on expert opinion regarding the clinical utility of CTA plaque imaging. Please help us gather this important data. After filling out the demographic portion (D1-12), please address the 7 clinical scenarios which are presented with a brief review of the pertinent literature, and answer the multiple choice questions (CT1-7). The survey will take no more than 20 minutes to complete. Comments on each case are welcome.

Demographics

D1. I am a

- a. cardiologist
- b. radiologist
- c. internist
- d. other; please specify

D2. My primary interest is

- a. cardiac CT
- b. nuclear
- c. intervention
- d. prevention
- e. general cardiology
- f. other; please specify

D3. I am board certified in

- a. CTA
- b. Nuclear
- c. Intervention
- d. Lipidology
- e. Radiology
- f. Other; please specify

D4. I have personally had a CTA

- a. yes
- b. no

D5. I have personally had a calcium scan

- a. yes
- b. no

D6. I personally interpret CTA's

- a. yes
- b. no

D7. I personally order CTA's

- a. yes
- b. no

D8. I personally order calcium scans

- a. yes
- b. no

D9. I analyze plaque on CTA's

- a. always
- b. sometimes
- c. never
- d. NA

D10. Plaque analysis should be reported

- a. always
- b. sometimes
- c. never

D11. Plaque analysis should affect decision meeting

- a. always
- b. sometimes
- c. never

D12. I practice evidence based, guideline recommended medicine

- a. always
- b. sometimes
- c. never

D13. I consider myself a CT expert.

- a. Yes
- b. No

Clinical Scenarios

1. Downgrading level of medical treatment in asymptomatic intermediate and high risk patients without plaque.

According to the 2020 ACC/AHA Guidelines for Assessment of Risk in Asymptomatic Adults (1), coronary artery calcium scanning (CAC) scanning “is reasonable for cardiovascular risk assessment in asymptomatic adults at intermediate risk” with a Class IIa recommendation. High risk patients are not addressed in these guidelines but the 2010 Appropriate Use Criteria for Cardiac Computed Tomography place this group in an “uncertain” category for both CAC and Coronary CTA (2). Although the use of CTA for this purpose is not “appropriate”, it is often performed for “appropriate” indications such as chest pain evaluation, “uncertain” indications such as risk assessment in high risk patients, and “inappropriate” indications such as risk assessment in intermediate risk patients. Plaque analysis can be readily performed, but there is no guidance for incorporating the absence of calcified and noncalcified plaque into decision making in the intermediate and high risk groups.

Example: A 68 year old male smoker, not on statin therapy, with hypertension and hyperlipidemia and a 22% Framingham 10 year risk, underwent CTA for risk assessment. The CAC was 0 and there was no noncalcified plaque. Lipids: TC 192 LDL 123 HDL 52 TG 85.

Question CT1: In asymptomatic patients classified as intermediate and high risk by Framingham or ESC criteria, is it appropriate to downgrade risk and decrease the level of medical therapy in the setting of a 0 CAC and absence of noncalcified plaque?

A. Intermediate risk patients

- a. Yes
- b. No

B. High risk patients

- a. Yes
- b. No

2. Initiation of Aggressive Medical Therapy in Patients with 0 CAC Scores and Noncalcified Plaque.

The importance of risk stratification in patients with a family history of premature coronary artery disease has resulted in the extension of “appropriate” CAC scanning to otherwise low risk patients (2). Again, the use of CTA for this purpose is not “appropriate”, but since CTA in these patients may be performed for “appropriate” indications such as chest pain evaluation, noncalcified plaque identification is a frequent occurrence.

Example (Figure 1): A 35 year old male underwent CTA for evaluation of chest pain; his father had a myocardial infarction at age 42. The CAC was 0, and 2

ulcerated plaques were noted in the proximal LAD; there was no obstructive disease. Lipids: TC 164 LDL 103 HDL 40 TG 103.

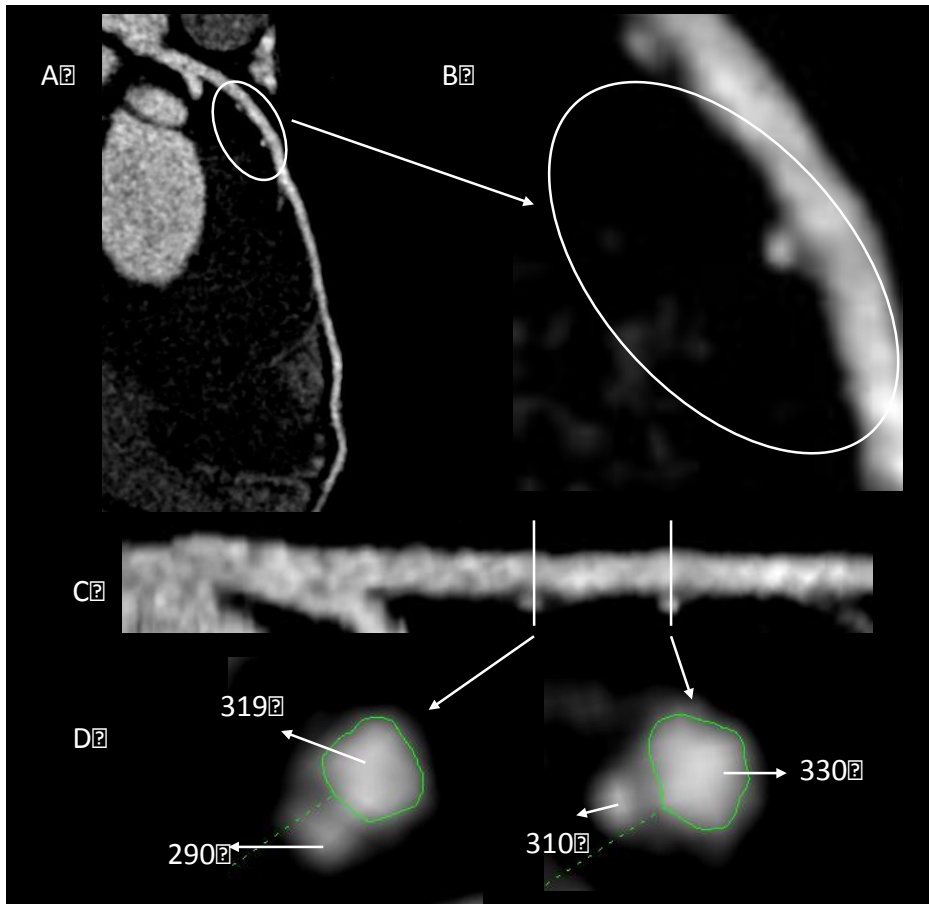


Figure 1: Unmagnified (A) and magnified (B) views of the LAD revealing 2 ulcerated plaques. Cross sections of the straightened MPR demonstrate the HU of the lumen and the ulcerated plaques

Question CT2. In asymptomatic patients with a positive family history of premature coronary disease, a 0 CAC and high risk noncalcified plaque, is it appropriate to initiate aggressive statin therapy?

- a. Yes
- b. No

3. Disease Progression and Treatment Evaluation

There is an increasing body of work documenting the strong association of CAC progression with poorer outcomes in asymptomatic patients (3), but serial CAC scanning is not “appropriate”. Noncalcified and calcified plaque progression on CTA have had very limited investigation. Lehman, et al (4), compared 8,311 coregistered cross sections in 69 patients at a 2 year interval. There were significant increases in the number of cross sections containing any plaque and noncalcified plaque, but calcified plaque segments were unchanged.

Cardiovascular risk factors, smoking and baseline plaque were independently associated with plaque progression. Inoue, et al (5), evaluated the effect of fluvastatin on CTA plaque volume in 32 patients after a median 12 months of treatment. The plaque volume change were significantly greater in the 24 statin treated patients than in the 8 in the control group.

Example (Figure 2): A 48 year old female with a positive family history of premature coronary disease, treated hypertension and hyperlipidemia, presented to the emergency department with chest pain 2 years after a CTA that demonstrated mild calcified plaque. Repeat CTA revealed an increase in the calcified component with development of significant low density noncalcified plaque and luminal narrowing, representing treatment failure.

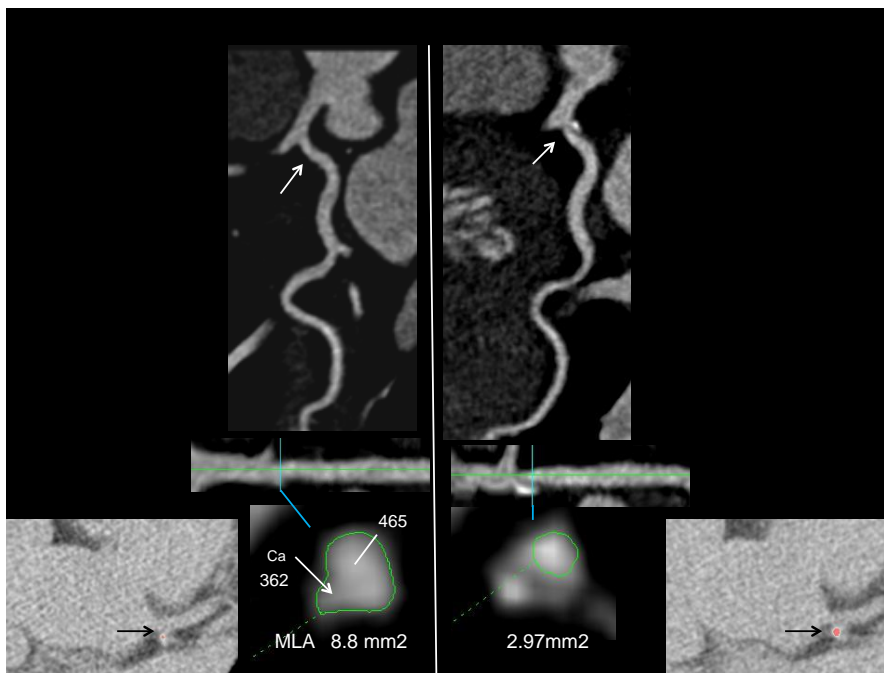


Figure 3: Left: MPR of LCx demonstrating mild calcified plaque confirmed on the noncontrast CT (insert). Right: 2 years later the calcified plaque has increased, with significant MLA reduction and new noncalcified plaque.

Example (Figure 3): A 47 year old male with hypertension and hyperlipidemia underwent CTA for chest pain evaluation; CAC was 1 and there was a 50-70% proximal left anterior descending stenosis secondary to noncalcified plaque with a low attenuation component and a borderline minimal luminal area. Myocardial perfusion imaging was normal and aggressive medical therapy was instituted. CTA was repeated 2 years later for recurrent chest pain. The CAC increased to 16, but the previously noncalcified plaque had become calcified, accounting for the increase, and there was a decrease in the low attenuation plaque volume; the minimum luminal area was unchanged.

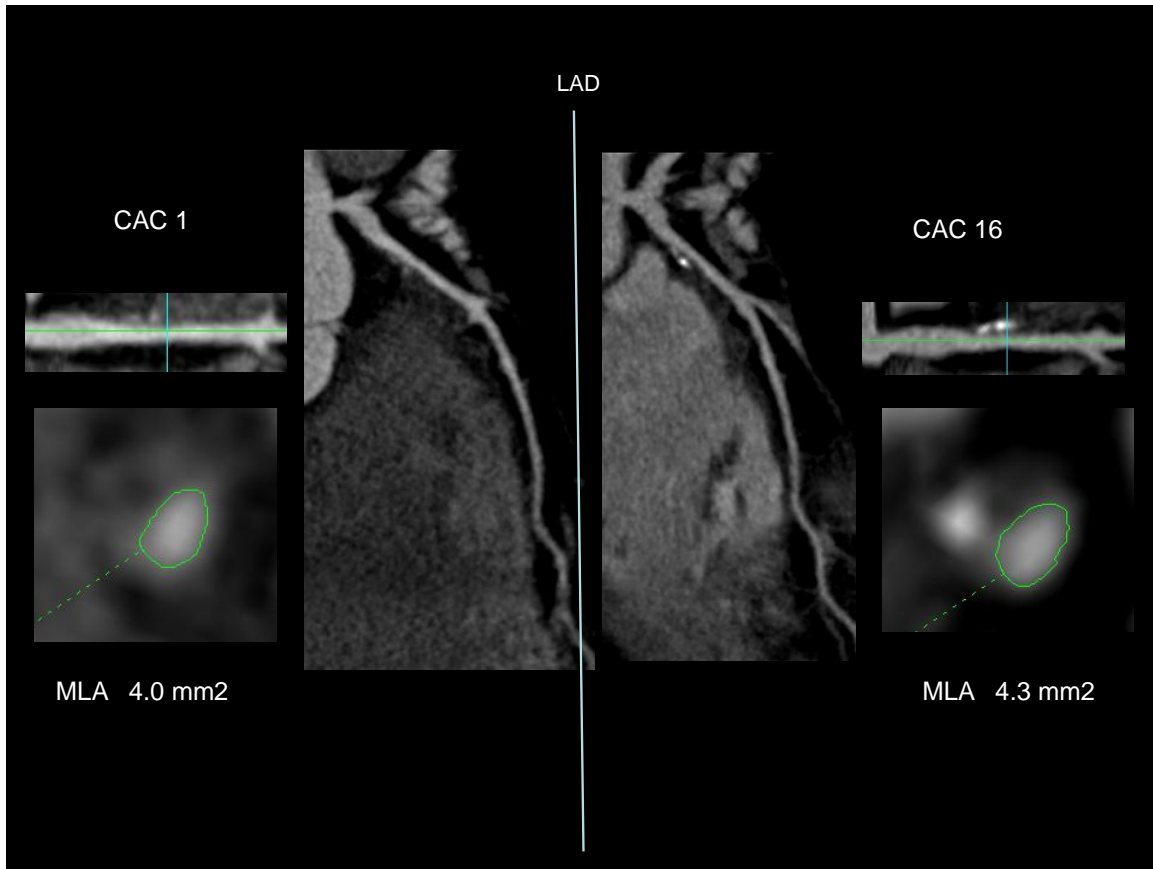


Figure 3: Left: MPR of LAD demonstrating 50-75% proximal LAD stenosis and borderline MLA of 4 mm². CAC was 1. Right: CAC has increased to 16 with calcification of previously noncalcified plaque and no change in MLA.

Question CT3. Is it appropriate to use changes in plaque on serial scanning to influence medical therapy?

A. Changes in calcified plaque

- a. Yes
- b. No

B. Changes in noncalcified plaque

- a. Yes
- b. No

4. Ultra-aggressive Treatment of Nonobstructive Lesions

There are no data justifying stenting nonobstructive lesions on the basis of high risk plaque characteristics. In the 3 year follow up period of 697 patients with acute coronary syndromes in the PROSPECT trial (6), events were related to nonculprit lesions (mean diameter stenosis 32.3±20.6%) in 11.6% of patients. Compared to nonculprit lesions that were not associated with events, those that were had >70% plaque burden (hazard ratio 5.03), minimal luminal area ≤ 4mm² (hazard ratio 3.21) or were thin-cap fibroatheromas by radiofrequency IVUS (hazard ratio, 3.35). However, even when all 3 were present the recurrent event

rate was only 18.2%, and was only 4.9% for thin cap fibroatheromas. The very poor specificity precludes prophylactic intervention on non-symptom producing high risk lesions, but the appropriate level of medical therapy has not been determined.

Example (Figure 4): A 66 year old male with chest pain was noted to have less than 50% proximal RCA stenosis with CTA features of spotty calcification, low attenuation plaque and positive remodeling.

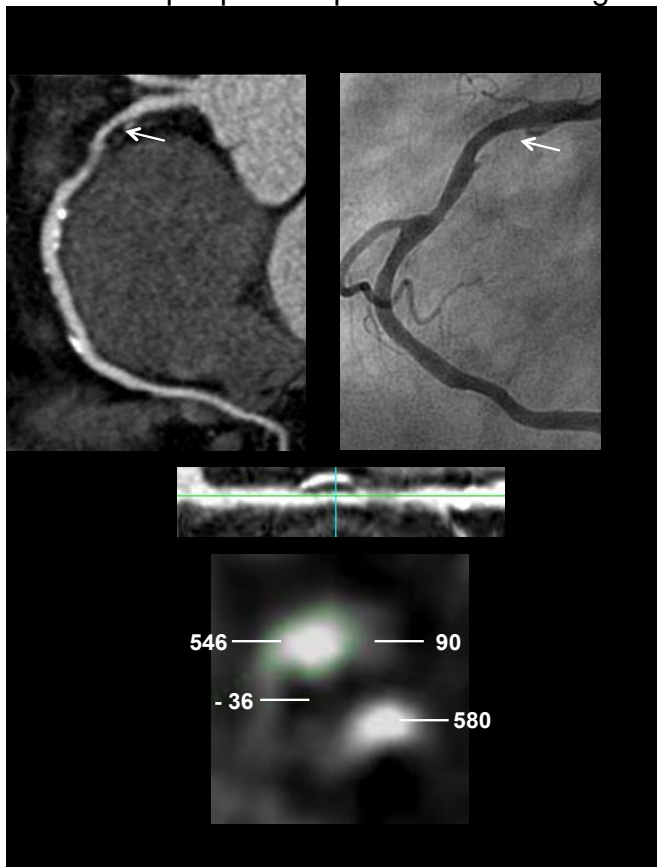


Figure 4: Upper left and bottom: MPR of RCA reveals a low density lipid core adjacent to the lumen, spotty calcification and positive remodeling of a <50% stenosis. Upper right: Corresponding coronary angiogram.

Question CT4. In patients with high risk plaque nonobstructive lesions is it appropriate to initiate ultra-aggressive medical therapy?

- a. Yes
- b. No

5. Accelerate Timing of Percutaneous Coronary Interventions

The CTA features of high risk plaques have been well documented. Motoyama, et al, (7) followed 1059 patients with suspected or known coronary disease for 27 ± 10 months after CTA. Those who developed acute coronary syndromes had significantly more positive remodeling, greater low attenuation (<30 HU) plaque

volume and greater percentage of low attenuation plaque than patients who remained free of events. Acute coronary syndromes developed in 22.2% of the 45 patients with both positive remodeling and low attenuation plaque compared 3.7% of the 27 patients with plaques displaying only 1 feature and 0.5% of the 820 patients with neither ($p < 0.001$). The ACS hazard ratio for those with either or both features was 22.8 ($p < 0.001$). Madder, et al, (8) performed CTA in 60 unstable angina patients. Of 294 plaques identified by CTA, 109 (37%) had features suggestive of disruption. Disrupted plaques were significantly more often complex by invasive coronary angiography, larger, more often positively remodeled, and had larger low attenuation (<50 HU) plaque volumes compared to nondisrupted plaques.

Optical coherence tomography and CTA were performed in 81 patients with 122 lesions; 37 were and 85 were not thin cap fibroatheroma (TCFA) by optical coherence tomography criteria (9). Plaque attenuation of TCFA was significantly lower and remodeling index was greater compared to the plaques with thicker fibrous caps. Plaque attenuation directly, and remodeling index inversely, correlated with fibrous cap thickness. Independent predictors of TCFA were mean <62.4 HU (odds ratio 8.20 $p < 0.0005$), remodeling index >1.08 (odds ratio 6.10, $p < 0.0012$), and signet ring like appearance (odds ratio 6.33, $p < 0.0014$).

Example (Figure 5): CTA was performed in a 65 year old male with several months of stable exertional angina. The culprit lesion had high risk features: a low attenuation lipid core adjacent to the lumen, spotty calcification and positive remodeling.

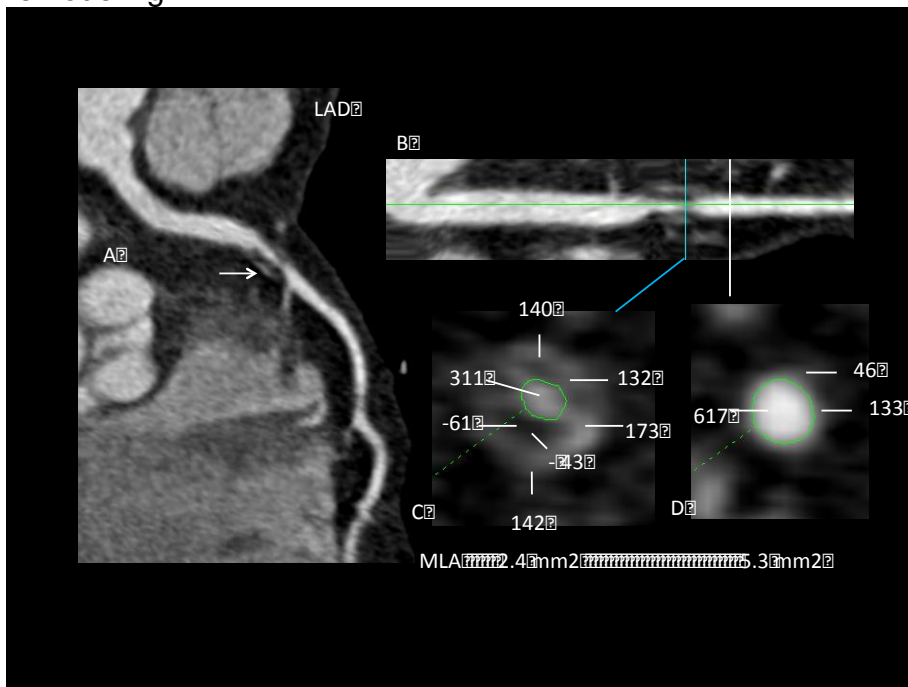


Figure 5: MPR of LAD (A) demonstrates a subtotal occlusion of the LAD (arrow). Right: Cross sectional analysis (C) of the straightened MPR (B) reveals low

density lipid (-61HU) adjacent to the lumen, areas of spotty calcification (132-173HU) and major positive remodeling compared to the normal segment (D).

Question CT5: In patients with stable angina who meet PCI appropriateness criteria, is it appropriate to accelerate the timing of intervention if they have a high risk plaque lesion?

- a. Yes
- b. No

6. Modify Interventions to Prevent PCI Complications

Recent studies have highlighted CTA plaque characteristics associated with PCI complications. Watabe, et al (10), performed CTA in 107 stable angina patients before PCI and compared plaque characteristics in the 36 with troponin elevations >3 times the upper limit of normal (0.010 ng/ml) post PCI to the 71 with lower troponin. Attenuation values were significantly lower, remodeling index was significantly higher, and spotty calcification was more frequent in the elevated troponin group. Multivariate analysis revealed odds ratios of 4.54 for remodeling index >1.05, and 4.27 for spotty calcification. When all 3 characteristics were present, the positive predictive value for elevated cTnT was 94%. When all were absent the negative predictive value was 90%. Kodama, et al (11), evaluated CTA plaque characteristics in 40 patients who developed slow flow during PCI compared to 40 matched controls who had uneventful procedures. The positive remodeling index was significantly higher and plaque density was significantly lower in the slow flow group. Circumferential plaque calcification (CPC) was significantly more frequent in the SF group 63% vs 5%, ($p < 0.001$) in the slow flow group, with an odds ratio of 79 ($p < 0.0001$) compared to the no slow flow group.

Example (Figure 6): CTA in a 62 year old female with stable angina revealed CPC, positive remodeling, and low attenuation plaque. In this scenario, it has been hypothesized that a downstream “basket” would decrease the likelihood of slow flow post PCI.

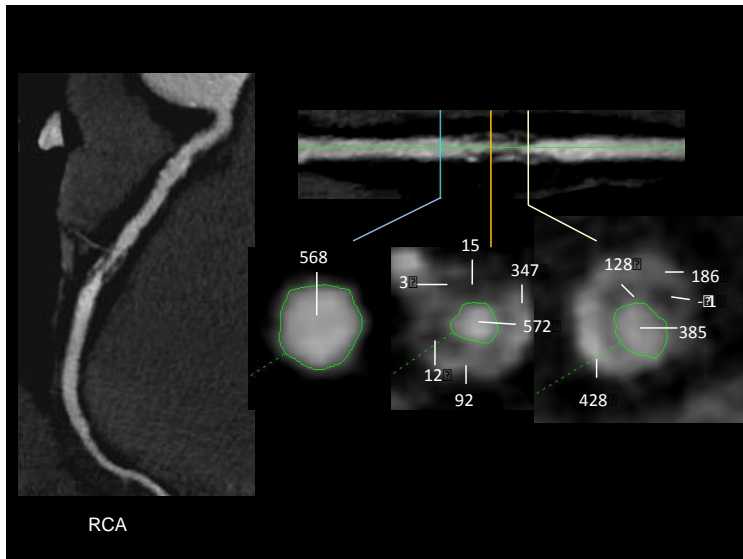


Figure 6: Left: MPR demonstrates >70% mid RCA stenosis. Right: Cross sectional analyses reveal severe luminal reduction, CPC, low attenuation plaque adjacent to the lumen and positive remodeling (RI 1.32) compared to the normal segment.

Question CT6: In patients with plaque characteristics that are more likely to produce distal embolic events during PCI, is it appropriate to consider a downstream protection device.

- a. Yes
- b. No

7. Override Fractional Flow Reserve (FFR) Criteria

FFR has become the gold standard for determining the functional significance of a stenosis; values ≤ 0.80 justify PCI in the appropriate clinical setting. In the FAME study (12), 1,005 patients with multivessel CAD were randomized to angiography or FFR guided PCI with stenting only for $\text{FFR} \leq 0.80$. Mortality and myocardial infarction rates were lower in the FFR guided PCI compared to the angiography guided group: 8.4% vs. 12.9%, $p = 0.02$. In the $\text{FFR} > 0.80$ deferred group, myocardial infarction rare was 0.2%; there were no deaths. In FAME 2 (13), patients in whom at least one stenosis was associated with an $\text{FFR} \leq 0.80$ were randomized to FFR-guided PCI plus the best available medical therapy or the best available medical therapy alone. In 888 who underwent randomization, the event rate was significantly lower in the PCI compared to the medical group (4.3% vs. 12.7, hazard ratio 0.32, $P < 0.001$), driven entirely by fewer urgent revascularization in the PCI compared to the medical therapy group (1.6% vs. 11.1%; hazard ratio, 0.13, $p < 0.001$).

Example (Figure 7): A 65 year old male with stable classic angina on dual anti-anginal therapy underwent CTA that revealed an intermediate stenosis with positive remodeling, low attenuation plaque and spotty calcification (Figure 4).

Invasive angiography confirmed an intermediate RCA stenosis and the FFR was 0.81.

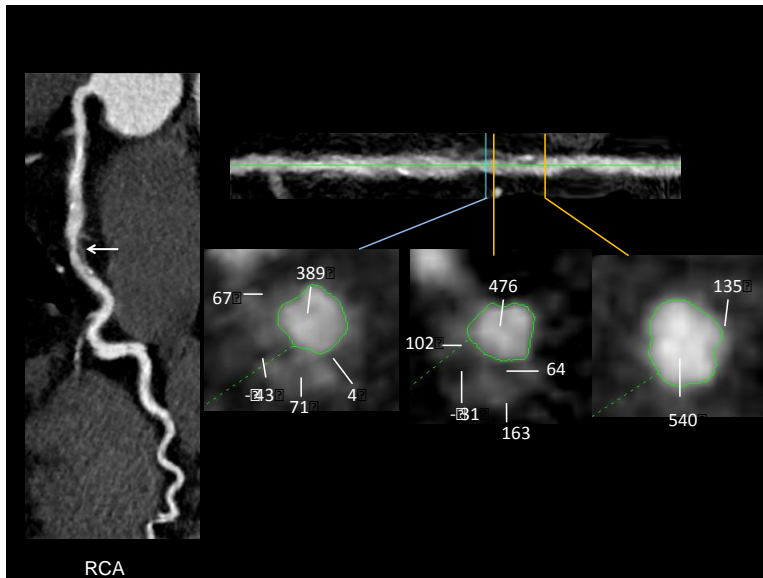


Figure 7: Left: MPR of the RCA demonstrates intermediate mid RCA stenosis (arrow). Right: Cross sectional analyses reveal low attenuation plaque adjacent to the lumen (-43HU, -31HU), spotty calcification (163HU) and positive remodeling compared to the normal segment (RI 1.18).

Question CT7. In borderline FFR situations, is CTA evidence of a high risk plaque lesion sufficient to convert medical management to a PCI scenario?

- a. Yes
- b. No

References

1. Greenland P, Alpert JS, Beller GA, et al. 2010 ACCF/AHA guideline for assessment of cardiovascular risk in adults. A report of the American College of Cardiology Foundation/American Heart Association Task Force on Practice Guidelines. J Am Coll Cardiol 2010; 56:e50 – e103.
2. Taylor AJ, Cerqueira M, Hodgson JM, et al. ACCF/SCCT/ACR/AHA/ASE/ASNC/SCAI/SCMR 2010. Appropriate use criteria for cardiac computed tomography. J Am Coll Cardiol 2010;56:1864 – 94.
3. Hecht HS. Subclinical atherosclerosis imaging comes of age: coronary artery calcium in primary prevention. Current Opinion in Cardiology. 2012.

4. Lehman SJ, Schlett CL, Bamberg F, et al. Assessment of coronary plaque progression in coronary computed tomography angiography using a semiquantitative score. *J Am Coll Cardiol Img* 2009;2:1262–70.
5. Inoue K, Motoyama S, Sarai M, et al. Serial Coronary CT Angiography–Verified Changes in Plaque Characteristics as an End Point Evaluation of Effect of Statin Intervention. *J Am Coll Cardiol Img* 2010;3:691–8.
6. Stone GW, Maehara A, Lansky AJ, et al. A prospective natural-history study of coronary atherosclerosis. *N Engl J Med* 2011;364:226-35
7. Motoyama S, Sarai M, Harigaya H, et al. Computed tomographic angiography characteristics of atherosclerotic plaques subsequently resulting in acute coronary syndrome. *J Am Coll Cardiol* 2009;54:49–57.
8. Madden RD, Chinnaiyan KM, Marandici AM, Goldstein J. Features of disrupted plaques by coronary computed tomographic angiography correlates with invasively proven complex lesions. *Circ Cardiovasc Imaging*. 2011;4:105-13.
9. Ito T, Terashima M, Kaneda H, et al. Comparison of In vivo assessment of vulnerable plaque by 64-slice multislice computed tomography versus optical coherence tomography. *Am J Cardiol* 2011;107:1270–7.
10. Watabe H, Sato A, Akiyama D, et al. Impact of coronary plaque composition on cardiac troponin elevation after percutaneous coronary intervention in stable angina pectoris: A computed tomography analysis. *J Am Coll Cardiol* 2012;59:1881–8.
11. Kodama T, Kondo T, Oida A, et al. Computed tomographic angiography–verified plaque characteristics and slow-flow phenomenon during percutaneous coronary intervention. *J Am Coll Cardiol Intv* 2012;5:636–43
12. Pijls NHJ, Fearon WF, Tonino PAL, et al. Fractional flow reserve versus angiography for guiding percutaneous coronary intervention in patients with multivessel coronary artery disease: 2-year follow-up of the FAME (Fractional Flow Reserve Versus Angiography for Multivessel Evaluation) Study
13. Bruyne BD, Pijls NHJ, Kalesan B, et al. Fractional flow reserve–guided PCI versus medical therapy in stable coronary disease. *N Engl J Med* 2012;367:991-1001.

CTA Plaque Analysis Survey Answer Sheet

Demographics

D1.

- a.
- b.
- c.
- d.

D2

- a.
- b.
- c.
- d.
- e.
- f.

D3

- a.
- b.
- c.
- d.
- e.
- f.

D4

- a.
- b.

D5.

- a.
- b.

D6

- a.
- b.

D7

- a.
- b.

D8

- a.
- b.

D9

- a.
- b.
- c.
- d.

D10

- a.
- b.
- c.

D11.

- a.
- b.
- c.

D12

- a.
- b.
- c.

D13.

- a.
- b.

Clinical Scenarios

CT1A

- a.
- b.

Comments:

CT1B

- a.
- b.

Comments:

CT2

- a.
- b.

Comments:

CT3A

a.

b.

Comments:

CT3B

a.

b.

Comments:

CT4

a.

b.

Comments:

CT5

a.

b.

Comments:

CT6

a.

b.

Comments:

CT7

a.

b.

Comments: